

# Cortical Field of Origin of the Anterior Commissure of the Rhesus Monkey<sup>1</sup>

MARC L. JOUANDET AND MICHAEL S. GAZZANIGA

*Department of Neurology, Division of Cognitive Neurosciences, Cornell University Medical College, New York, New York 10021*

*Received April 11, 1979*

The full extent of the cortical field of origin of the anterior commissure of the rhesus monkey was mapped by horseradish peroxidase (HRP) histochemistry. Two adult monkeys were first subjected to complete callosal commissurotomies and permitted to fully recover 6 months prior to a second operation involving the massive unilateral injection of HRP into the entire left temporal lobe. Because the anterior commissure is the only direct fiber system ramifying to the contralateral cerebral cortical hemisphere following callosotomy, the only cells labeled with HRP in the uninjected hemisphere are those giving rise to the anterior commissure. Only layer III cortical pyramidal cells were labeled by HRP. The outer boundaries of the field of origin of the anterior commissure extend from the temporal pole to the occipitotemporal border and from the inferior half of the insular cortex to the parahippocampal gyrus. The field of origin delineated in the present investigation is much more extensive than the terminal projection field of the anterior commissure delineated by prior investigators utilizing silver degeneration methods.

## INTRODUCTION

The anterior commissure (AC) is anatomically unique among primate corticocortical fiber systems in that the outer boundaries of the field of origin and the terminal projection field can, at least theoretically, be precisely delineated within the cerebral cortices. Because the AC, unlike the intertwined intrahemispheric fiber systems, is, at the midline, a unitary fiber bundle, some unique anatomical manipulations exploiting the commissure's interhemispheric nature are possible. The pervasive afferent and efferent fibers of the corpus callosum arise and terminate within

Abbreviations: HRP—horseradish peroxidase, AC—anterior commissure.

<sup>1</sup> This work was supported by U.S. Public Health Service grant NS 15053 and the McKnight Foundation.

overlapping cortical territories, and the fibers within the corpus callosum are not organized in a strictly topographic manner, (13, 18), so that the cortical fields of origin and termination of portions of the corpus callosum become increasingly difficult to determine accurately as callosal sections become increasingly small.

The subcortical course of the AC and two of its three branches, pars olfactoria and pars interhemispherica, have been anatomically investigated in the human brain (14) by a freezing dissection technique, and in the rhesus monkey (7) by the Marchi method. The Fink–Heimer technique (6) was recently applied to investigate the distribution of AC fibers to the amygdaloid nuclei of the rhesus monkey (25). The origin and distribution of the third limb of the AC, the commissural component of stria terminalis, clearly described for the rat (3) and rabbit (26), has yet to be worked out for primate species.

The cortical terminal projection field of the AC was investigated electrophysiologically in the rhesus (15) and chimpanzee (1) by strychnine neuronography and anatomically by the Fink–Heimer technique in the rhesus monkey (30) and the squirrel monkey (19). Although these various approaches have led to some disagreement regarding the precise location and full extent of the cortical terminal projection field, there is general concurrence that the anterior inferotemporal region appears to be the cerebral cortical target for the AC fibers.

The extent and location of the cortical field of origin of the primate AC has never been systematically investigated. Marchi degeneration was found in the AC of the rhesus monkey after placement of a surface cortical lesion in the superior temporal gyrus (24). Nauta-Gygax degeneration was found in the rhesus AC only after inferotemporal, but not superior temporal, gyral lesions (28). The cortical cell types giving rise to the rhesus AC have never been identified.

The present experiment was designed to fully map the cortical field of origin and to identify the cell types which comprise the cortical field of origin giving rise to the AC of the rhesus monkey.

## METHODOLOGY

*Subjects.* Two adult rhesus monkeys, one male and one female, between 3 and 4 years of age, were subjected to neurosurgical operations under deep sodium pentobarbital anesthesia.

*Surgical Procedures.* The first operation involved the complete transection of the corpus callosum. The procedure for callosotomy were completely described elsewhere (9). The monkeys quickly recovered from this first operation and survived an additional 6 months. The monkeys then

underwent a second operation involving the massive injection of horseradish peroxidase (HRP, Sigma type VI) into the entire left temporal lobe. The temporal muscle was retracted over the zygomatic arch, the skull opened as low on the temporal bone as the retracted muscle allowed, and the dura gently incised and peeled back to reveal the posterior portions of the superior temporal gyrus, the sylvian fissure, and the vein of Labbé. The needle of a 10- $\mu$ l Hamilton syringe, mounted on a Kopf stereotaxic carrier, was visually guided into the brain along the general axes running from the posterior superior temporal gyrus to the inferomedial temporal pole. The plunger of the Hamilton syringe was hydraulically driven by a microinfusion pump set to deliver 0.2  $\mu$ l 35% HRP solution per minute. The Hamilton syringe was filled with 7  $\mu$ l HRP and inserted into the brain four times for a total injection of 28  $\mu$ l HRP solution in the temporal lobe of each animal. The injection needle was first deeply inserted, then the infusion pump activated, and the syringe slowly withdrawn, during 35 min, from its maximal depth to its point of insertion into the cortex. Thus, the HRP was injected, not at one site, but throughout the course of the needle tract. The four injection axes were (a) from the medial temporal pole to the inferior parietal cortex just dorsal to the sylvian fissure; (b) from the inferolateral temporal pole region to the middle portions of the superior temporal gyrus; (c) from the ventral surface of the posterior inferotemporal gyrus to the posterior superior temporal gyrus; and (d) from the occipital temporal border region to the posterior superior temporal gyrus. The purpose of these unconventionally massive injections was to label the entire rostrocaudal, mediolateral, and dorsoventral extent of the temporal lobe including the amygdala, the insular cortex, the temporooccipital and temporoparietal borders. The concentration and amount of HRP were designed to maximize the spread of label within the injected left temporal lobe. Usually, the spread of such label is something to be rigorously controlled if one wishes to label a circumscribed cell territory, lamina, or nucleus. In the case of the present experiment, however, it was reasoned that because the AC is the only fiber system ramifying to the contralateral cortical hemisphere after callosotomy, only the AC cells of origin in the hemisphere contralateral to the pervasive temporal lobe injection should be apparent after histochemical processing. It was hoped that the field of origin would not be underestimated and that the pervasive label would succeed in labeling completely the field of origin in the right hemisphere.

*Histological Processing.* The monkeys quickly recovered from the second operation and survived an additional 48 h. They were then given a lethal dose of sodium pentobarbital anesthesia and transcardially perfused with 2000 ml physiologic saline delivered at room temperature during 20 min. Subsequent to the 0.9% saline flush, approximately 2000 ml fixative,

consisting of 1.5% glutaraldehyde and 0.5% paraformaldehyde in a 0.1 M phosphate buffer (pH 7.4) was delivered at 4°C. Finally, 2000 ml 10% sucrose in 0.1 M phosphate buffer was delivered at 4°C. The cranium was then opened, the brain stereotaxically blocked in the skull, removed from the skull, and stored 8 h in the 10% sucrose phosphate buffer at 4°C, then placed in 20% sucrose buffer for an additional 8 h, and then in a 30% sucrose buffer, at 4°C for a final 8 h. The brain was then coronally sectioned at 40  $\mu$ m on an American Optical freezing microtome. The sections were stored about 24 h at 4°C in phosphate buffer and then mounted on chromealum-gelatin subbed slides and air dried 2 h. The tetramethyl benzidine histochemistry followed the procedures fully described elsewhere (16). The slides were washed in distilled water, taken through graded alcohols, cleared in xylene, and then coverslipped with Permount. These sections were not counterstained. A second series of unreacted sections were stained with cresyl violet.

## RESULTS

Although the HRP injections were massive in the left hemisphere, there was no diffusion of the label across the midline. Figure 1 shows the heavily labeled commissure in the noninjected hemisphere emerging from a dark surround 1 mm from the midline. The dark surround indicates that the tissue around the commissure was not labeled and proves the successful exploitation of the commissure's interhemispheric nature.

Cytoarchitecturally striking layer III cortical pyramidal cells were found whose proximal axons, apical, and basilar dendrites are clearly apparent (See Figs. 2a–c). Because only pyramidal cells were seen to be labeled by HRP, it is suspected that only these cell types give rise to the cortical component of the AC, and that only these cells comprise the cortical field of origin of the primate AC.

The field of origin of the anterior commissure extended from the temporal pole [Bonin and Bailey's (27) cytoarchitectonic area TG] to the occipitotemporal border (areas OA/TE), and from the inferior portions of the insular cortex to the parahippocampal gyrus (area TH). As seen in Figs. 3a and b (each representing data collected on individual monkeys), the field of origin was not entirely continuous and cells sometimes appeared in clumps separated by quiet zones; more often, however, entire layers were continuously labeled within certain gyri (see Fig. 4). Pyramidal cell density was invariably greatest on the lateral portions of the superior and inferior temporal gyri and indicates the presence of heavy rostrocaudal coursing bands. In the superior temporal gyrus, pyramidal cells were widely scattered within layer III (see Figs. 5a–c). In contrast, the pyramidal cells

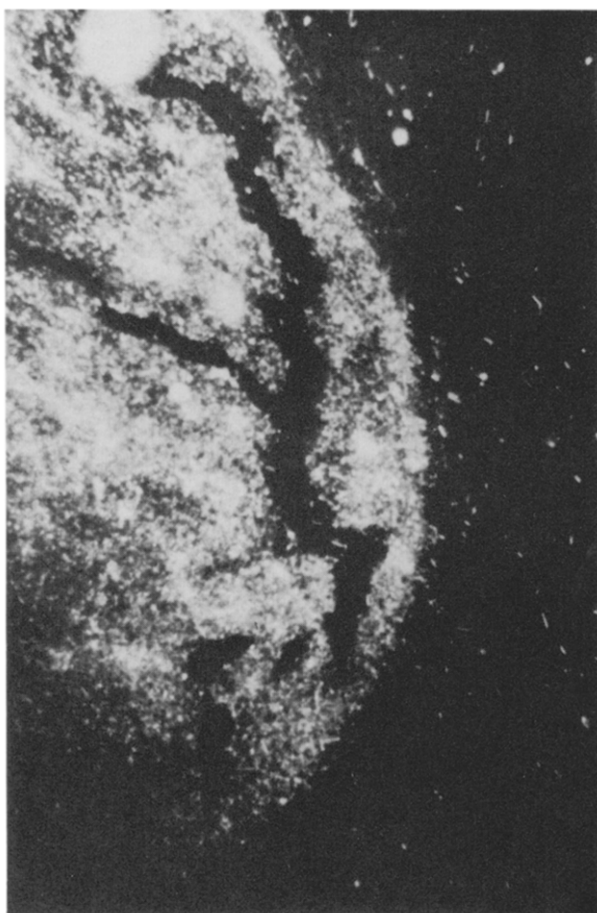


FIG. 1. The fibers of the anterior commissure, labeled by horseradish peroxidase, emerge from dark unlabeled surrounding tissue in the noninjected (right) hemisphere. The commissure, approximately 1 mm from the midline, appears as the head of a comet as it courses posteriorly into the coronal plane of section. Dark-field illumination; magnification  $\times 100$ .

of the inferotemporal region were tightly organized into a three- to five-cell-deep lamina within layer III (see Fig. 4). The presence of HRP-labeled cells in the insular cortex, the depths of the superior temporal sulcus, and the parahippocampal gyrus appeared to depend on rostrocaudal location. Proceeding caudally, the superior border of the field of origin moved progressively from the inferior half of the insular cortex and down around the lateral surface of the superior temporal gyrus, and the inferior border progressively invaded the more medial portions of the inferotemporal region to fade out within the parahippocampal gyrus.

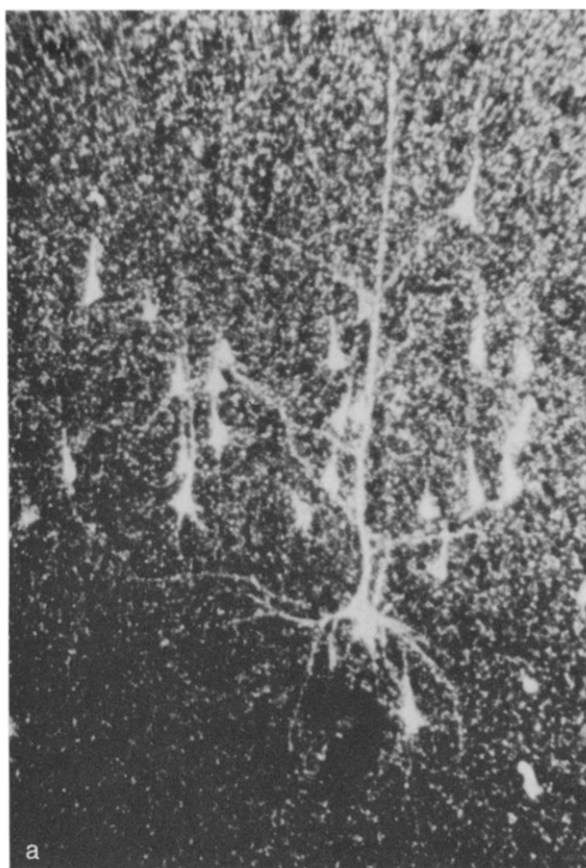
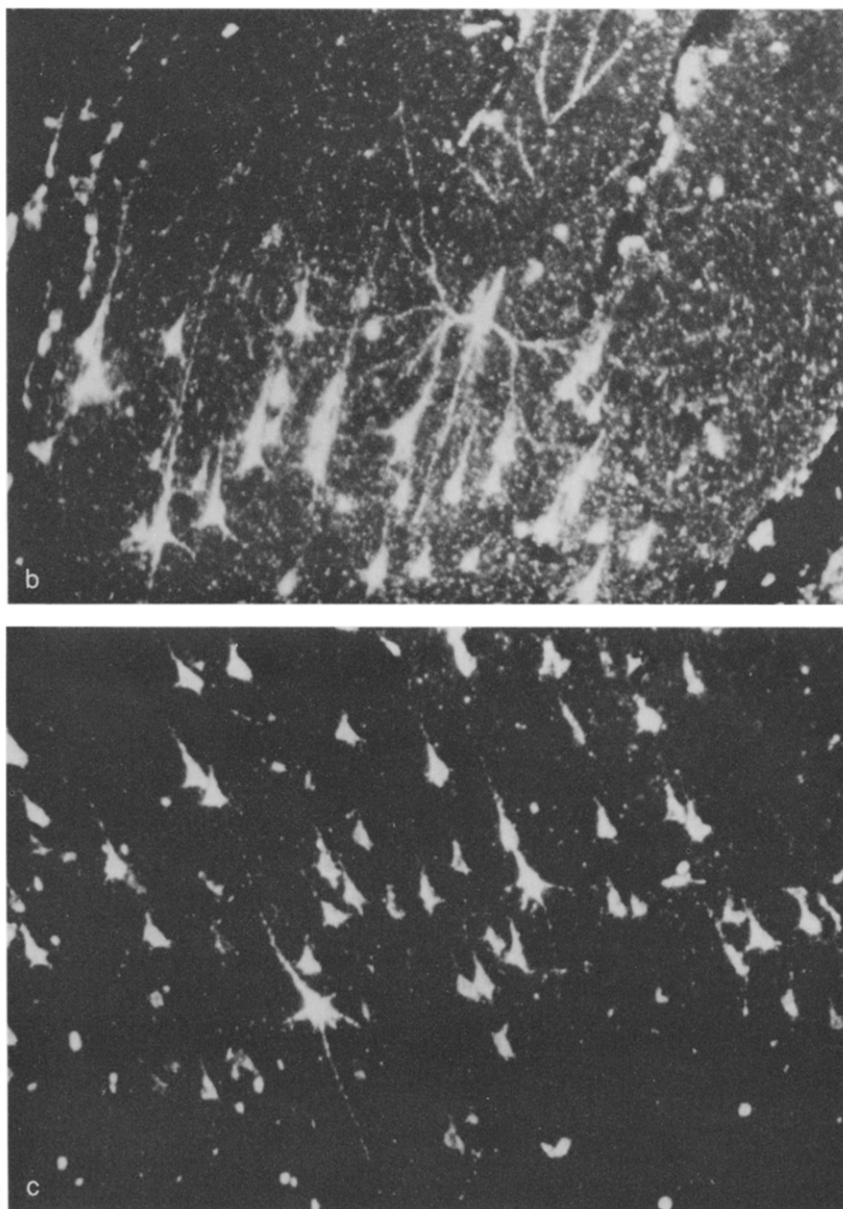


FIG. 2. Dark-field illumination (magnification  $\times 380$ ) of HRP-labeled layer III pyramidal cells whose proximal axons, basilar, and apical dendrites are apparent. The cells in a formed a small clump on the superior surface of the superior temporal gyrus. The cells in b and c were part of a densely populated laminar territory stretching within the entire superior-inferior extent of the lateral portion of the superior temporal gyrus.

In the two monkeys the entire temporal polar cortex, except for the medial side, possessed pyramidal cells giving rise to the AC. Within the lateral surface of the superior temporal gyrus, the heaviest concentration of cells was on the superior and inferior portions of the gyrus. The presence of cells in the depths of the superior temporal sulcus was usually discontinuous but seemed heavier in the more posterior coronal sections.

The olfactory bulb, the anterior olfactory nucleus, and the olfactory tubercles were not examined. Although fibers from the AC were found recently to terminate within certain amygdaloid nuclei (25), we were unable to positively identify any HRP-labeled cells within these structures.

FIGURE 2 (*Continued*)

No cells were observed to be labeled within the hippocampus. Because the dorsal and ventral hippocampal commissures cross the midline on the ventral surface of the corpus callosum, their fate was identical to that of the callosum.

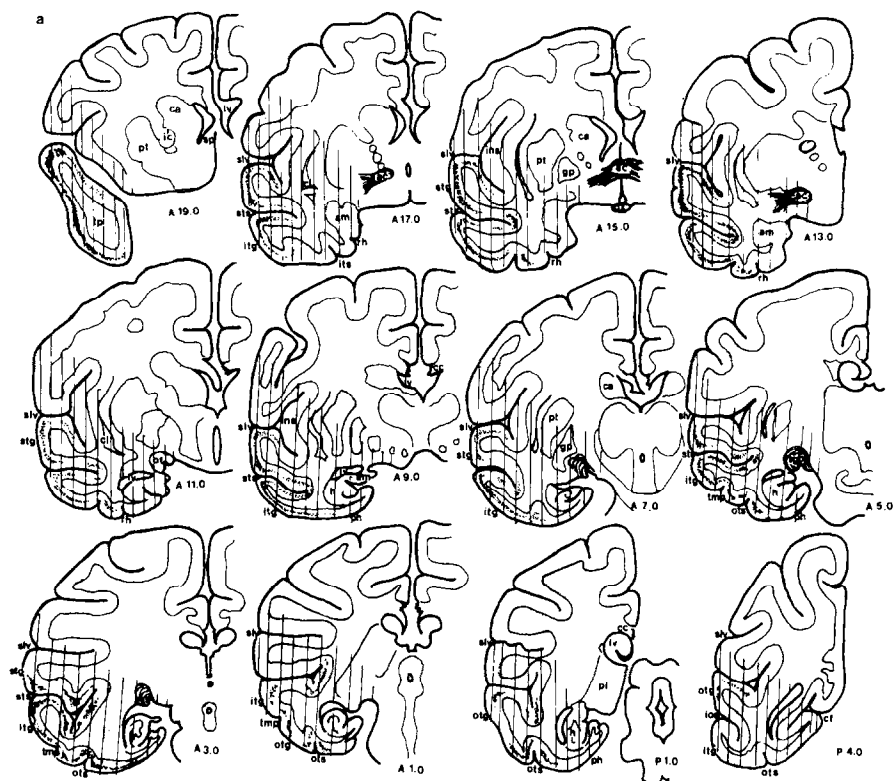


FIG. 3. a and b each represents serial coronal sections through the brain of an individual monkey. The relative density and extent of the dot pattern indicates the relative density and locale of HRP-labeled pyramidal cells in the noninjected, right hemisphere. The vertical lines indicate the extent of the diffusion of HRP within the injected, left hemisphere. The monkey is therefore "looking" at the reader. The numerical designations below each coronal section represent the anterior/posterior location according to the atlas of Snider & Lee (22). Abbreviations: ac—anterior commissure, am—amygdala, ca—candate, cc—corpus callosum, cf—calcarine fissure, cl—claustrum, ec—external capsule, gp—globus pallidus, h—hippocampus, ic—internal capsule, ins—insular cortex, ios—inferior occipital sulcus, itg—inferotemporal gyrus, its—inferotemporal sulcus, lgb—lateral geniculate body, lv—lateral ventricle, otg—occipitotemporal gyrus, ots—occipitotemporal sulcus, ox—optic chiasm, ot—optic tract, ph—parahippocampal gyrus, pl—pulvinar, pt—putamen, rh—rhinal fissure, tmp—posterior mid-temporal sulcus, sp—septum, stg—superior temporal gyrus, sts—superior temporal sulcus, slv—sylvian fissure.

## DISCUSSION

The cortical field of origin of the anterior commissure of the rhesus monkey, as mapped within the present study (see Fig. 6), it much more extensive than the cortical terminal projection field of the commissure as



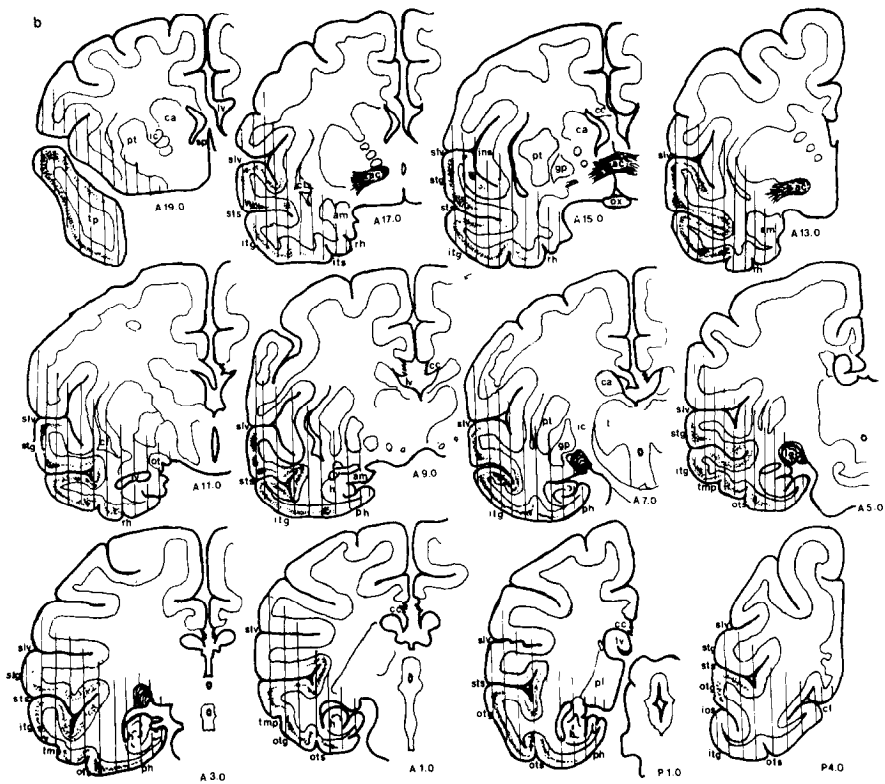


FIGURE 3 (Continued)

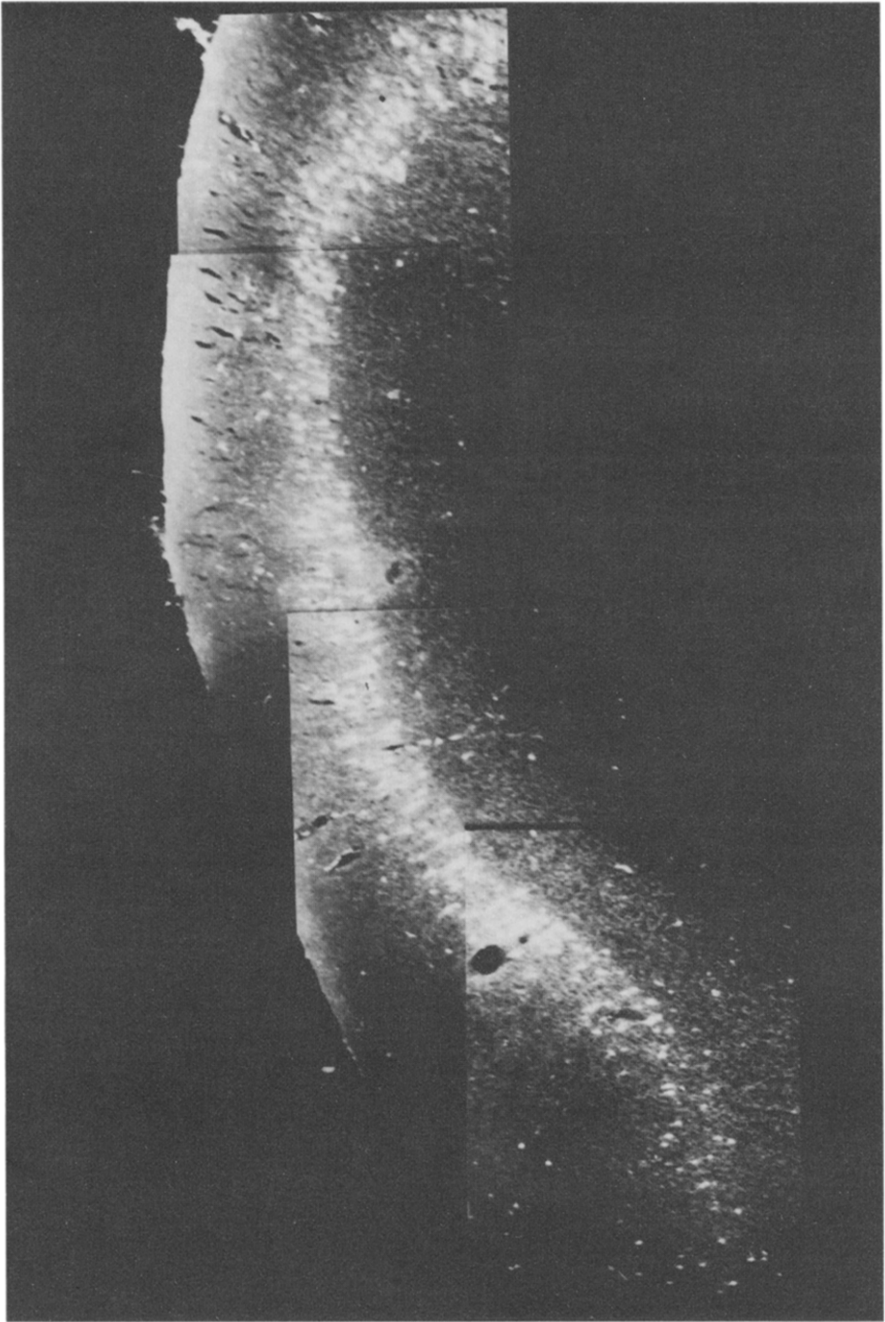


FIG. 4. Montage of extensively labeled lamina within layer III throughout the entire superior-inferior extent of the inferotemporal gyrus. The HRP-labeled pyramidal cells are tightly organized into a four- to six-cell-deep lamina. Dark-field illumination; each photomicrograph is  $\times 100$ .

unable to determine exactly where these fibers terminated—whether in the parahippocampal cortex, Ammon's horn, or the amygdala—and cautiously reserved judgment on the ultimate ramifications of these fibers. The authors were of the opinion that no fibers projected to the superior temporal gyrus.

Sunderland (24), however, found Marchi degeneration in the AC of a rhesus monkey having a surface cortical lesion of the anterior third of the superior temporal gyrus. Sunderland apparently destroyed some cells giving rise to the AC.

Through their investigation of the subcortical course of the human AC, Klinger and Gloor (14) largely verified the findings of Fox *et al.* (7) with the exception that they observed the pars olfactoria in man to be even further reduced in significance. Although the freezing dissection technique applied by Klinger and Gloor (14) exquisitely revealed many subcortical fiber systems and the course of the AC into the temporal lobe, the technique distorted cortical structure and therefore could not shed any light on the extent of the neocortical fields of origin or termination of the AC.

Investigating the terminal projections of corticofugal fibers from the temporal lobe of the rhesus monkey, Whitlock and Nauta (28) observed some degeneration in the AC when lesions were placed in the anterior and posterior portions of the inferotemporal gyrus. In contrast to Sunderland's (24) findings, Whitlock and Nauta (28) did not observe degeneration in the AC when lesions were placed in the superior temporal gyrus.

More recently, Zeki (30), utilizing the Wittanen (29) modification of the Fink–Heimer technique, attempted to map the neocortical projection field of the AC of the rhesus monkey. According to his findings, the posterior limb ramified almost exclusively to the anterior temporal cortex surrounding caudally the temporal pole; this projection zone extended from the depths of the inferotemporal gyrus and stretched up the medial surface to fade out in the parahippocampal gyrus. However, Zeki (30) did not examine the superior temporal gyrus for degenerated material and, therefore, may have failed to delineate completely the terminal projection field of the AC of the rhesus monkey.

Pandya *et al.* (19) mapped the terminal projection field of the anterior commissure of the squirrel monkey by combining ultrasonic lesions of the commissure with the Fink–Heimer silver degeneration technique. Their results agreed with those of Zeki (30) with the exception that they also saw degeneration in the anterior superior temporal gyrus, the inferior insular cortex, and depths of the superior temporal sulcus. The sonic lesions of the anterior commissure were, however, incomplete.

The extent of the AC field of origin mapped in the present investigation is somewhat at odds with the extent of the terminal projection field mapped

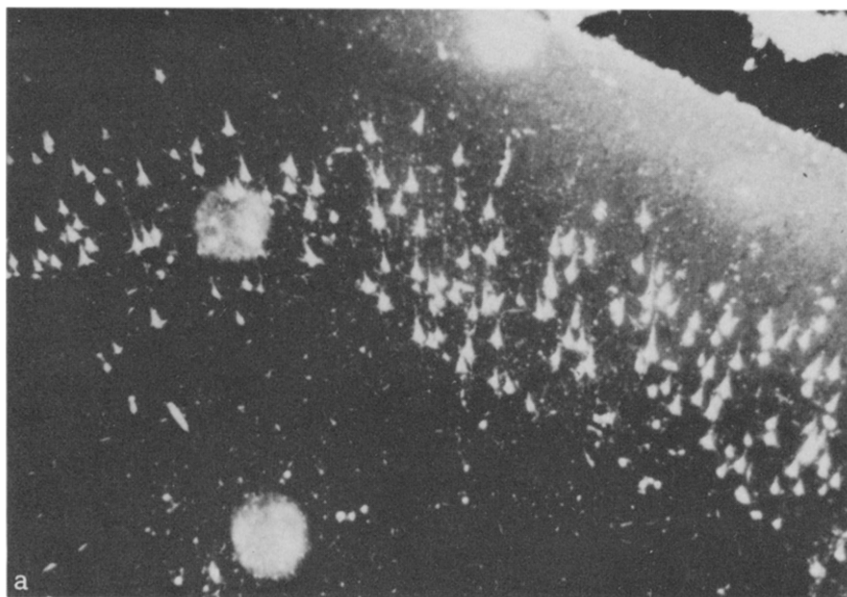


FIG. 5. a—HRP-Labeled pyramidal cells are distributed 10 to 12 cells deep within layer III on the superior lateral surface of the superior temporal gyrus. b and c—the labeled cells on the inferior lateral surface of the superior temporal gyrus are also loosely organized within layer III.

by these earlier studies (19, 30). If the AC does, in actuality, project in a homotopic and truly commissural fashion to the contralateral cerebral hemisphere, then the previous delineations clearly underestimate the terminal projection field's actual size. Such discrepancies may simply reflect the relative sensitivities of the anatomical techniques exploiting retrograde axoplasmic transport mechanisms and fiber degeneration. If, however, the previous reports were correct, then we are forced to conclude that an extensive cortical field of origin projects through the commissure to a highly compact and restricted terminal projection field. Van Alphen's (26) experimental anatomical investigation on the anterior commissure of the rabbit tends to support this view. Van Alphen demonstrated that a very wide cortical field of origin projected through the commissure to terminate not in the cortex, but rather, heterotopically in the basal telencephalic structures of the contralateral hemisphere. Taken together, the investigations of Van Alphen (26) on the rabbit, and De Olmos and Ingram (3) on the rat, appear to suggest that the homotopic projections of the AC tend to be the exception rather than the rule. Although Van Alphen (26) demonstrated AC projections to the amygdala, he could not identify amygdaloid projections into the AC and suggested that the source of these fibers could be found in the neocortex and prepiriform cortex. De Olmos and Ingram (3), in contrast, demonstrated a commissural connection between the amygdaloid

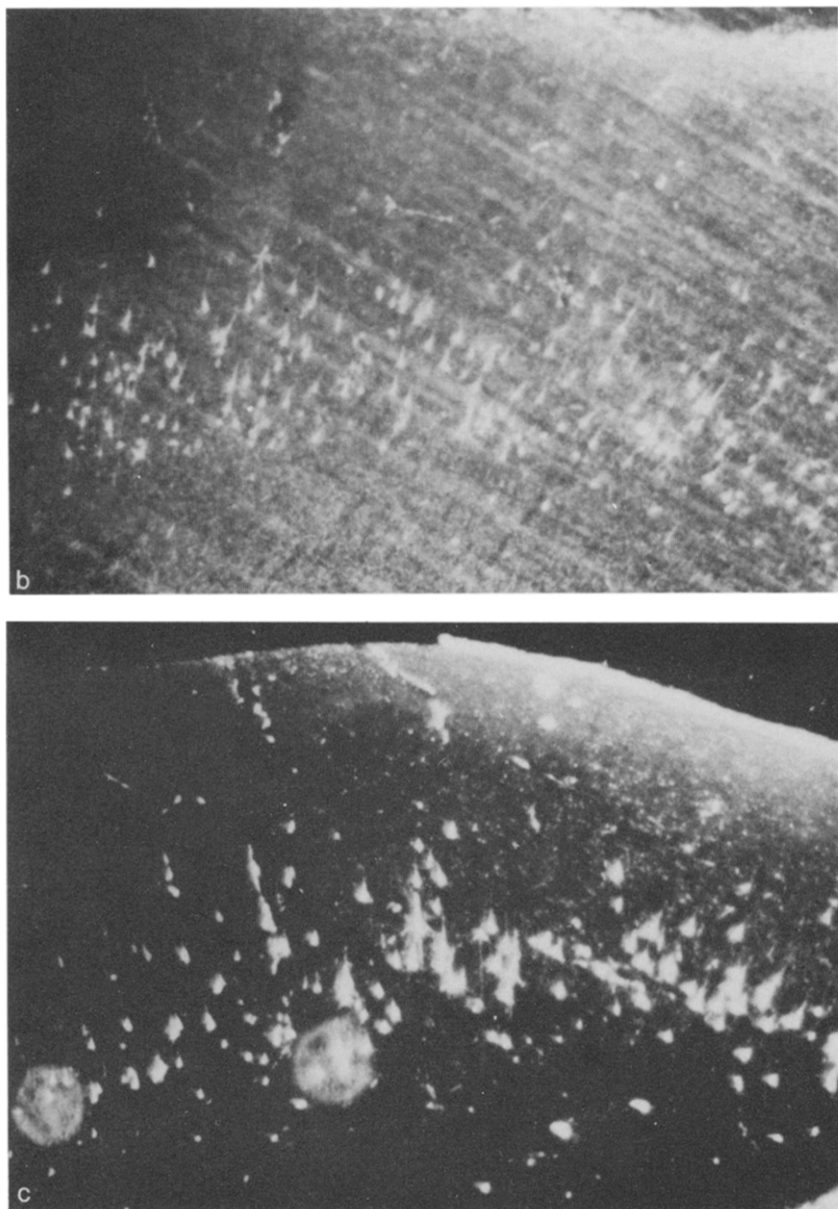


FIGURE 5 (Continued)

nuclei of each hemisphere via the commissural component of stria terminalis. More recently, Turner *et al.* (25) transected the AC of the rhesus monkey, applied the Fink–Heimer technique, demonstrated AC fibers to the amygdala, and speculated that these fibers had their origin in the

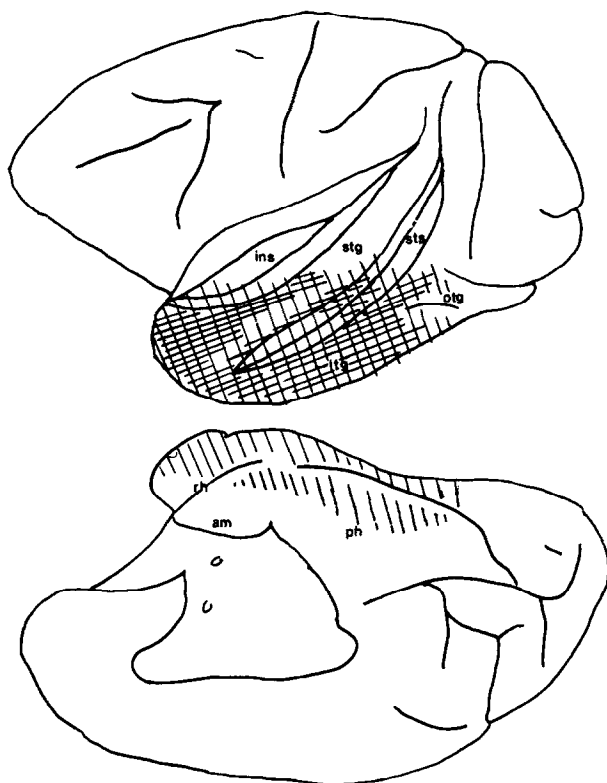


FIG. 6. The full extent of the field of origin of the AC reconstructed from the serial sections of Figs. 3 a and b is indicated by the diagonal lines and crosshatching which shows the territories with the greatest density of pyramidal cells. Abbreviations as in Fig. 3.

contralateral amygdaloid complex. In our own material, we were unable to clearly identify HRP-labeled cell bodies in the various amygdaloid nuclei. Although this would suggest an organization somewhat akin to that observed in the rabbit, on the basis of two subjects we cannot rule out the possibility that the amygdaloid nuclei do, in fact, give rise to a major commissural projection to the AC. There is a need for further research on this point.

Although it is not at all unlikely that the AC may project in a heterotopic fashion to the contralateral temporal cortex, there is some electrophysiologic evidence that increases our suspicions that the fields of origin and termination may, in fact, overlap (11, 15). The strychnine neurographic data of McCulloch and Garol (15) indicated an extensive AC terminal projection field in the rhesus monkey—the entire lateral surface of the inferotemporal gyrus from the temporal pole to the occipitotemporal border.

In addition to having mapped the terminal field of the commissure, Zeki (30) also examined the temporal lobe terminal projection field of the splenium of the corpus callosum, observed the splenial projection to be quite extensive, and noted that the anterior border of this temporal splenial projection to be somewhat more rostral than the caudal boundary of the AC terminal field. The field of origin outlined in the present study, therefore, appears to overlap in a major fashion with the terminal projections of the splenium of the corpus callosum.

In addition to the anatomic overlays, recent electrophysiologic data indicate that the AC and the splenium carry similar visual information: the AC projects to cells in the inferotemporal cortex that have precisely the same function as those cells innervated by the splenium—visual units having binocular/bilateral receptive fields (11). On the basis of Zeki's (30) contention that the anterior commissure does not project to the posterior temporal cortex, Gross *et al.* (11) postulated the existence of an interneuronal circuit receiving AC visual information in the anterior temporal cortex and relaying the information to the binocular/bilateral visual units of the posterior inferotemporal gyrus. Assuming homotopic reciprocity between the AC fields of origin and termination, the interneuron postulated by Gross *et al.* (11) is unnecessary.

Our own data indicate that pyramidal cells giving rise to the AC are situated in the same region—the inferotemporal and occipitotemporal gyri—from which Gross *et al.* (11) sampled their binocular/bilateral visual cells. Perhaps we might speculate that these visual units send their axons through the AC to the contralateral temporal cortex.

The interhemispheric transfer of visual information via the AC has been well documented in nonhuman primates (2, 8, 17, 21, 23), and in man (10). In addition, recent neuropsychological examinations of patients with corpus callosotomy having intact anterior commissures revealed auditory, visual, and olfactory information transfer and variability among these patients in the efficiencies of modality specific transfer through the AC (20).

## REFERENCES

1. BAILEY, P., H. W. GAROL, AND W. S. MCCULLOCH. 1941. Cortical origin and distribution of corpus callosum and anterior commissure in the chimpanzee. *J. Neurophysiol.* **4**: 564–571.
2. BLACK, P., AND R. E. MYERS. 1964. Visual function of the forebrain commissures in the chimpanzee. *Science* **146**: 799–800.
3. DE OLMOS, J. S., AND W. R. INGRAM. 1972. Projection field of stria terminalis in the rat brain: An experimental study. *J. Comp. Neurol.* **146**: 303–334.
4. EBNER, F. A. 1969. A comparison of primitive forebrain organization in metatherian and eutherian mammals. *Ann. N.Y. Acad. Sci.* **167**: 241–257.
5. EBNER, F. F., AND R. E. MYERS. 1965. Distribution of corpus callosum and anterior commissure in cat and raccoon. *J. Comp. Neurol.* **124**: 353–365.

6. FINK, R. P., AND L. HEIMER. 1967. Two methods for selective silver impregnation of degenerating axons and their synaptic endings in the central nervous system. *Brain Res.* **4**: 369–374.
7. FOX, C. A., R. R. FISHER, AND S. J. DESALVA. 1948. Distribution of the anterior commissure in the monkey (*Macaca mulatta*). *J. Comp. Neurol.* **89**: 245–278.
8. GAZZANIGA, M. S. 1966. Interhemispheric communication of visual learning. *Neuropsychologia* **4**: 183–189.
9. GAZZANIGA, M. S. 1970 *The Bisected Brain*. Appleton–Century–Crofts, New York.
10. GAZZANIGA, M. S., G. L. RISSE, S. P. SPRINGER, E. CLARK, AND D. H. WILSON. 1975. Psychologic and neurologic consequences of partial and complete cerebral commissurotomy. *Neurology* **25**: 10–15.
11. GROSS, C. G., D. B. BENDER, AND M. MISHKIN. 1977. Contributions of the corpus callosum and the anterior commissure to visual activation of inferior temporal neurons. *Brain Res.* **131**: 227–239.
12. HEATH, C. J., AND E. G. JONES. 1971. Interhemispheric pathways in the absence of a corpus callosum: An experimental study of commissural connections in the marsupial phalanger. *J. Anat.* **109**: 253–270.
13. KAROL, E. A., AND D. N. PANDYA. 1971. The distribution of the corpus callosum in the rhesus monkey. *Brain* **94**: 471–486.
14. KLINGER, S., AND P. GLOOR. 1960. The connections of the amygdala and of the anterior temporal cortex in the human brain. *J. Comp. Neurol.* **115**: 333–369.
15. MCCULLOCH, W. S., AND H. W. GAROL. 1941. Cortical origin and distribution of corpus callosum and anterior commissure in the monkey. *J. Neurophysiol.* **4**: 555–563.
16. MESULAM, M. M. 1978. Tetramethyl benzidine for horseradish peroxidase neurohistochemistry: A non-carcinogenic blue reaction product with superior sensitivity for visualizing neural afferents and efferents. *J. Histochem. Cytochem.* **26**(2): 106–117.
17. NOBLE, J. 1968. Paradoxical interocular transfer of mirror-image discrimination in the optic chiasm sectioned monkey. *Brain Res.* **10**: 127–151.
18. PANDYA, D. N., E. A. KAROL, AND D. HEILBRONN. 1971. The topographical distribution of interhemispheric projections in the corpus callosum of the rhesus monkey. *Brain Res.* **32**: 31–43.
19. PANDYA, D. N., E. A. KAROL, AND LELE. 1975. The distribution of the anterior commissure in the squirrel monkey. *Brain Res.* **49**: 177–180.
20. RISSE, G. L., J. LEDOUX, S. P. SPRINGER, D. H. WILSON, AND M. S. GAZZANIGA. 1978. The anterior commissure in man: Functional variation in a multi-sensory system. *Neuropsychologia* **16**: 23–31.
21. ROCHA-MIRANDA, C. E., D. B. BENDER, C. G. GROSS, AND M. MISHKIN. 1975. Visual activation of neurons in the inferotemporal cortex depends upon striate cortex and forebrain commissures. *J. Neurophysiol.* **38**: 475–491.
22. SNIDER, R. S., AND J. C. LEE. 1961. *A Stereotaxic Atlas of the Monkey Brain (Macaca Mulatta)* Univ. of Chicago Press, Chicago.
23. SULLIVAN, M. V., AND C. R. HAMILTON. 1973. Interocular transfer of reversed and nonreversed discriminations via the anterior commissure in monkeys. *Physiol. Behav.* **10**: 355–359.
24. SUNDERLAND, S. 1940. The distribution of commissural fibers in the corpus callosum in macaque monkey. *J. Neurol. Psychiatry* **3**: 9–18.
25. TURNER, B. H., M. MISHKIN, AND M. E. KNAPP. 1979. Distribution of the anterior commissure to the amygdaloid complex in the monkey. *Brain Res.* **162**: 331–337.
26. VAN ALPHEN, H. A. M. 1969. The anterior commissure of the rabbit. *Acta Anat (Basel)* **57**: 1–112.



27. VON BONIN, G., AND P. BAILEY. 1947. *The Neocortex of Macaca mulatta*. Urbana, Univ. of Illinois Press.
28. WHITLOCK, D. G., AND W. J. H. NAUTA. 1956. Sub-cortical projections from the temporal neocortex in *Macaca mulatta*. *J. Comp. Neurol.* **106**: 183–212.
29. WITTANEN, J. T. 1969. Selective silver impregnation of degenerating axons and axon terminals in the central nervous system of the monkey (*Macaca mulatta*). *Brain Res.* **14**: 546–548.
30. ZEKI, S. M. 1973. Comparison of the cortical degeneration in the visual regions of the temporal lobe of the monkey following section of the anterior commissure and the splenium. *J. Comp. Neurol.* **148**: 167–176.